

A Case Report on Wellens Syndrome: The Widow Maker

Himanshu Jain, Ajay P. Tripathi , Anudeep Dubey, Sukriti Maheshwari, Vijay Garg

Wellens syndrome is the typical clinical electrophysiological presentation in patients with critical LAD stenosis. This rare entity is often missed if unrecognized and has considerable implications due to critical stenosis associated with it. It is also known as "The Widow Maker." It is further divided into type A and B type A is recognized by t-waves that are biphasic in leads V2 and V3, while Type B is characterized by deeply symmetrical T-wave inversions in leads V2 and V3, often including leads V1 and V4 and sometimes leads V5 and V6. It is important to recognize this as symptoms are intermittent and often do not correlate with clinical severity. PCI is the management of choice. Here we present a case of Wellens syndrome presented in our Institute with typical history found associated with it.

Access this article online

Website:

www.cijmr.com

Keywords:

Wellens syndrome, LAD stenosis, clinical severity

10.58999/cijmr.v2i01.28

Introduction

Wellens syndrome presents with typical cardiac chest pain, more often intermittent, without any Cardiac enzymes abnormalities and few t-wave abnormalities¹ in ECG. It represents a pre-infarction stage of the myocardium; if not recognized, it may lead to massive transmural ischemia. It is referred to as the widow maker as it has disastrous consequences (for the patient as well as the family). It was in the early 1980s. The syndrome was first identified by Dr. De Zwann, Wellens, and colleagues. They noted that 75% of patients with these ECG findings went on to develop acute, anterior, wall, and myocardial infarction within weeks if they were treated with only medical management. Cardiac catheterization with percutaneous coronary intervention is the definitive treatment to relieve the occlusion..

Case Presentation

A 40 year old male presented to us with complaints of classical cardiac chest pain, diffuse, retrosternal, radiating to both his arms and back, intermittent in nature, relieved by rest and associated with perspiration and sense of impending doom. There was no trigger he was able to recall for his pain. The patient was immediately given the cardiac loading dose & was

started on antiplatelets, statins, low molecular weight heparin, nitrates, ACE inhibitors, beta blockers and other supportive therapy. There was no previous history of any syncopal attack or palpitations. There was no h/o Diabetes or hypertension. The patient was a chronic cigarette smoker (Bidi) with h/o 25 pack year of smoking and chronic alcoholic with the frequency of twice- thrice in a week and approx. 180 mL (1quarter) of hard spirit taken in each sitting.

On examination, his vitals were BP-110/70 mmHg, P-98/min Spo2-98% on room air, JVP – Not raised, No pedal Edema. His systemic examination was unremarkable, without any focal signs.

Investigations

ECG- shows sinus rhythm, rate 70/min regular, normal axis, There was 1- mm ST elevation in Lead II, III, avF and biphasic T waves were seen in Lead V1-V3.

Other investigations, CBC, ESR, chest X-ray, LFT, KFT, HbA1C, and electrolyte panel was normal. His Troponin I was Negative and CK-MB was 174. 2D echo 2 was suggestive of normal LV systolic function, LVEF 62%, no RWMA, all cardiac chambers were normal, all valves were normal.

Due to classical presentation & ECG changes, we suspected Wellens syndrome and a cardiologist

Department of Medicine, Ruxmaniben Deepchand Gardi Medical College, Ujjain, Madhya Pradesh, India

Correspondence to: Himanshu Jain, Department of Medicine, Ruxmaniben Deepchand Gardi Medical College, Ujjain, Madhya Pradesh, India. E-mail: himanshu08jain@gmail.com

Submitted: 03/05/2022

Revision: 08/09/2022

Accepted: 12/02/2023

Published: 20/05/2023

This is an open access journal, and articles are distributed under the terms of the Creative Commons Attribution-NonCommercial-ShareAlike 4.0 License, which allows others to remix, tweak, and build upon the work non-commercially, as long as appropriate credit is given and the new creations are licensed under the identical terms.

How to cite this article: Jain H, Tripathi AP, Dubey A, Maheshwari S, Garg V. A Case Report on Wellens Syndrome: The Widow Maker. Central India Journal of Medical Research. 2023;2(1):29-31.

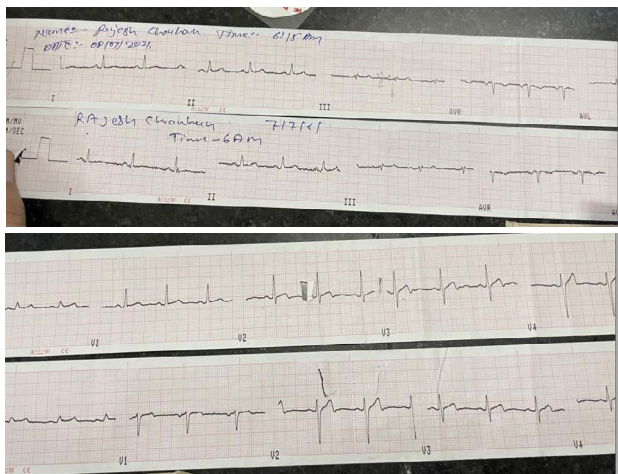


Figure 1: ECG showing biphasic T waves in Lead V1-V3 while 1-mm ST elevation is seen in Lead II III

consultation was taken, after which the patient was posted for cardiac catheterization and coronary angiography.

On CAG, the patient has Proximal LAD 100% block, was filling retrograde from RCA.

Treatment

The patient was initially managed conservatively with low molecular weight heparin, dual antiplatelet, statins, ACE inhib, beta blockers & nitrates. A PCI to LAD was done the very next day, and a stent was placed in LAD.

After PCI intervention, the patient's clinical symptoms resolved and they recovered uneventfully. He was discharged with the advice of regular follow-up once in 15 days.

Discussion

Wellens syndrome represents a pre-infarction state of coronary artery disease. Dyslipidemia, hypertension, diabetes, sedentary lifestyle, obesity, familial history, and smoking are the risk factors for Wellens syndrome, which are the same as those for coronary artery disease.

Patients with Wellens syndrome usually exhibit symptoms consistent with acute coronary syndrome. Chest pain is the typical symptom induced by physical activity and relieved by rest. The pain may radiate to the neck, jaw, or shoulder. Patients should be pain-free upon presentation to the emergency department. However, the ECG pattern as described below may persist. Patients typically appear comfortable with an unremarkable physical exam though they may demonstrate some mild distress with diaphoresis, similar to those with acute myocardial infarction.

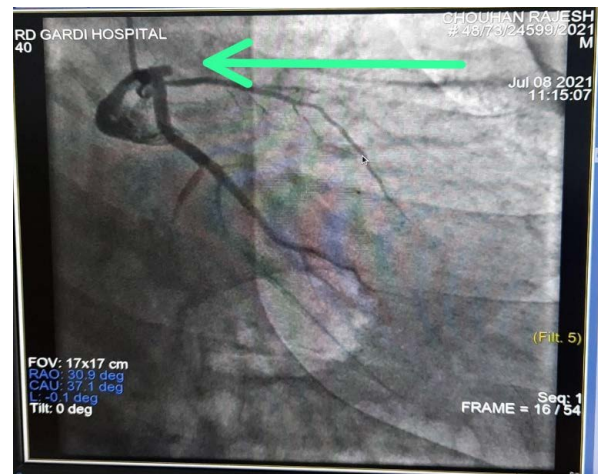


Figure 2: CAG Plate showing Proximal LAD occlusion.

Wellens syndrome is further divided into Type A and B, type A is recognized by biphasic T-waves in leads V2 and V3, while Type B is characterized by deeply symmetrical T-wave inversions in leads V2 and V3, often including leads V1 and V4 and sometimes leads V5 and V6.

Many cases are reported in the literature about this syndrome.^{2,3}

This was a case of Type A Wellens syndrome. This case has a history of typical intermittent angina. Similar cases have also been reported in the literature.⁴

If unrecognized, it has ominous progression into massive transmural ischemia in LAD territory, anterior wall, earning it the nickname of "The Widow Maker".⁵

There are case reports describing Wellens syndrome presenting without typical chest pain.⁶ Therefore, its recognition by ECG changes again holds paramount importance.

Further, Wellens syndrome can also present as Epigastric pain or Syncope as reported,⁷ therefore, it's a true masquerader.

It is important to recognize it early and all T wave changes especially when associated with chest pain of any type, must be taken seriously and serial ECG monitoring, 2D echo and then as in this case, Coronary angiography must be planned for them.

It is important not to miss T wave changes in an ECG as non-specific as they may be signs of underlying ominous disease.⁸

Conclusion

1. Wellens syndrome represents a typical ECG presentation in a case with Critical LAD stenosis.
2. It represents a pre-infarction state of coronary

artery disease, and the patient may go on to develop myocardial infarction soon if not managed aggressively.

3. It is important to recognize this as symptoms are intermittent and often do not correlate with clinical severity.
4. Medical management alone has not been found to be effective.
5. PCI is the management of choice.

Conflict of Interest & Funding Statement

None to declare

Consents

All the explained consents were taken in the appropriation of the case report that will not reveal the sole identity of the patient.

References

6. Win Htut Oo, Swe Zin Mar *et al.*, 'Omnious T-Wave Inversions: Wellens' Syndrome Revisited', *Journal of community hospital internal medicine perspectives*, 6, 4 (2016), 32011
7. Serdar Ozdemir *et al.*, 'Wellens' Syndrome - Report of Two Cases', *Turkish Journal of emergency medicine*, 15, 4 (2015), 179–81
8. Guillermo Pérez-Acosta, Paula Vega Ocaña and Luciano Santana-Cabrera, 'Wellens syndrome: Case report', *Medicina clinica* (2020)
9. Nastasi M. Intermittent Typical Angina: Remember Wellens' Syndrome. *Adv J Emerg Med*. 2019 Jun 9;3(3):e30. doi: 10.22114/ajem.v0i0.155. PMID: 31410407; PMCID: PMC6683594.
10. M. Yusuf Muharam, R. Ahmad and My Harmacy, 'The ' Widow Maker': Electrocardiogram Features That Should Not Be Missed', *Malaysian family physician : the official Journal of the Academy of Family Physicians of Malaysia*, 8, 1 (2013), 45–7
11. Torelli E, Sardeo F, Nuzzo E, Cicchinelli S, Petrucci M, Pignataro G, Covino M, Franceschi F, Candelli M. Wellens Syndrome without chest pain, is it possible? *Eur Rev Med Pharmacol Sci*. 2020 Jul;24(14):7718-7721. doi: 10.26355/eurev_202007_22275. PMID: 32744698.
12. Ajibawo T, Andreev A, Sahni S. Wellens' Syndrome Presenting as Epigastric Pain and Syncope: An Unusual Presentation. *Cureus*. 2020 Feb 4;12(2):e6877. doi: 10.7759/cureus.6877. PMID: 32190440; PMCID: PMC7057254.
13. Markayle R. Scheers, Bryan C. Sleight and Latha Ganti, 'Wellens' Syndrome: Is One Electrocardiogram Good and Plenty?', *Cureus*, 11, 4 (2019), e4394